

Growth Plate Stress Fractures in Teenage Climbers:

A guide for parents, coaches, GPs and hand surgeons

Teenage children who climb and train intensively are more at risk of epiphyseal (growth plate) stress fractures of the finger.

This guide aims to assist parents and coaches in identifying and avoiding the primary causes of growth plate stress fractures and provide advice for medical professionals on the treatment of such injuries.

Who is at risk?

Growth plate stress fractures most commonly occur in teenage climbers at the time of the pubertal growth spurt, often around the timing of breast growth for girls and pubic hair in boys. The fingers don't finish growing until around age 17.

The bone grows from the growth plate and is weakest at this point. Growth plates are significantly weaker than the surrounding tendons and ligaments and so are at increased risk of injury from any activity which loads the finger.

A growth plate and how bone grows

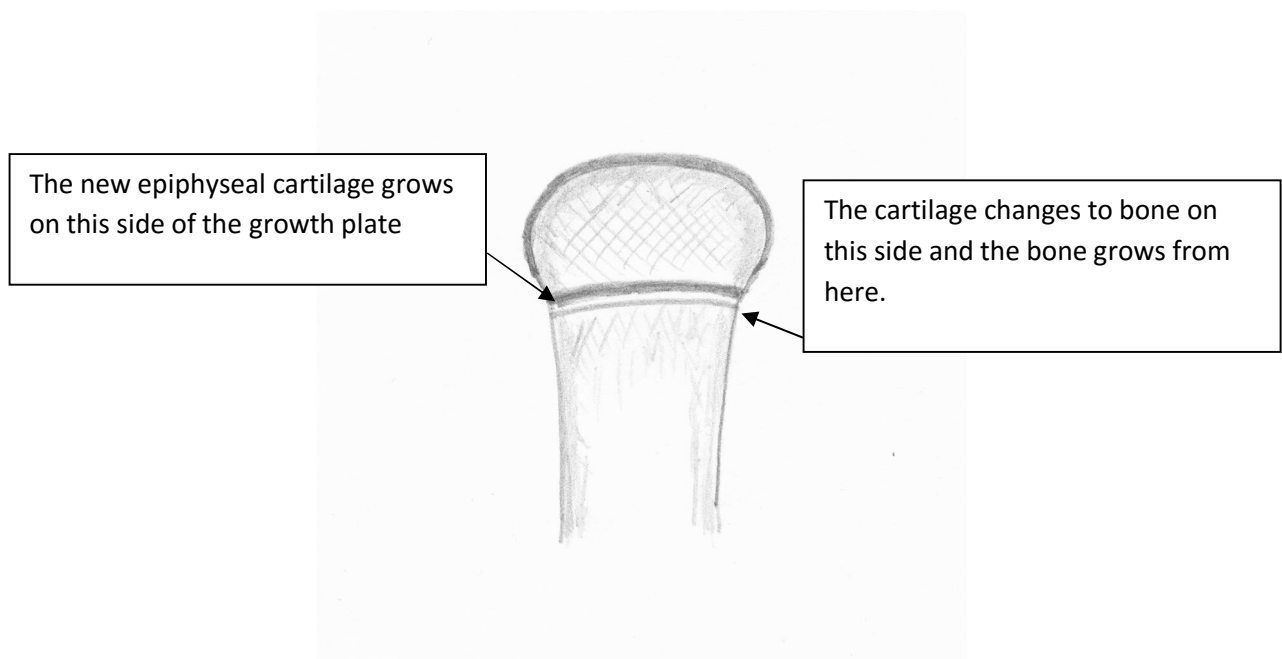


Figure 1 Normal Growth Plate

A stress fracture occurs over time rather than from one specific injury. The forces involved in climbing produce repetitive trauma to the fingers. This may decrease blood flow to the growth plate, decreasing mineralisation, which in turn weakens the growth plate junction. The forces generated on the growth plate especially from the crimping action used in climbing may pull it apart over time.

Growth plate stress fractures are not unique to the fingers of climbers and may be seen in other sports such as the forearm of young gymnasts and the shoulders of “little league” baseball players.

Pain = STOP!

If a young climber has persistent pain or pain that is stopping them moving, putting pressure through a limb or a finger etc or affecting how they are performing as an athlete they **SHOULD NEVER BE ALLOWED TO “work through the pain”**. They should be assessed by a doctor to ascertain whether they have an acute injury (one that has just happened) or pain due to overuse. If finger epiphyseal injuries are left untreated they can lead to disruption of bone growth, which may lead to permanent damage.

Epiphyseal injuries of the finger are most commonly reported in the middle and ring fingers. They tend to affect the finger joint nearest the hand, the proximal interphalangeal joint or PIP joint.

A stress fracture of the epiphysis of the PIP joint can be difficult to diagnose. Patients often complain of a slow onset of pain in the joint and sometimes notice a reduced range of movement. They may have some swelling and tenderness on the back of the PIP joint.

If young climbers experience these symptoms following training, they are likely to have an epiphyseal stress fracture and they **MUST** see their GP and insist on being referred to a hand surgeon urgently for experienced clinical review and further imaging. Even if nothing is seen on x-rays a focused MRI scan may confirm a stress fracture.

Advice for GPs and hand surgeons

The parents that have given you this leaflet will be concerned that their child has an epiphyseal stress fracture of a PIP joint caused by climbing.

They will often not have had a single episode of trauma but will have applied high loads through their PIP joints while climbing. The literature reports that the middle and ring fingers are most commonly affected since these take the most strain during the crimping grip when climbing (Crimping is method of gripping a hold in rock climbing and bouldering that relies only on the fingertips for support. It's characterized by the hyperextension of the first joint in the fingers and a contraction of the second joint.) With a stress fracture of the

epiphysis of the PIP joint climbers normally complain of a gradual onset of pain in the joint and sometimes a reduced range of movement. They will often have PIP joint swelling and dorsal tenderness. The fracture is normally on the dorsal aspect as the dorsal part of the epiphysis fuses last.

The young climber will normally be in their pubertal growth spurt (peak age range 12-13 for girls and 13-15 for boys for fractures, but they can occur earlier or later depending on growth spurt and fusion of epiphysis).

They need urgent referral to a hand surgeon for examination, imaging, treatment and advice regarding activity modification. There are several reports in the literature of growth arrest leading to angulation of the finger and long-term joint damage in teenagers who continue to climb with undiagnosed epiphyseal stress fractures.

The finding of dorsal swelling and pain in the middle or ring PIPJ. should raise a strong suspicion of a stress fracture in a young climber. The literature reports that imaging epiphyseal stress fractures is often difficult and may require multiple x-ray views of the joint, dynamic fluoroscopy or MRI to confirm the clinical diagnosis.

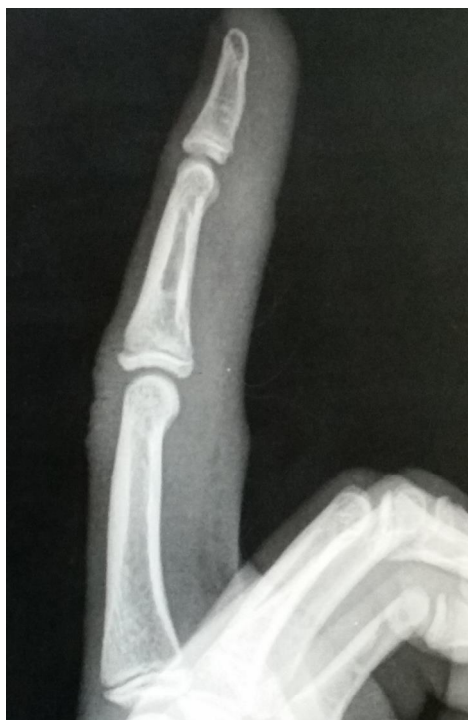

Fig.2

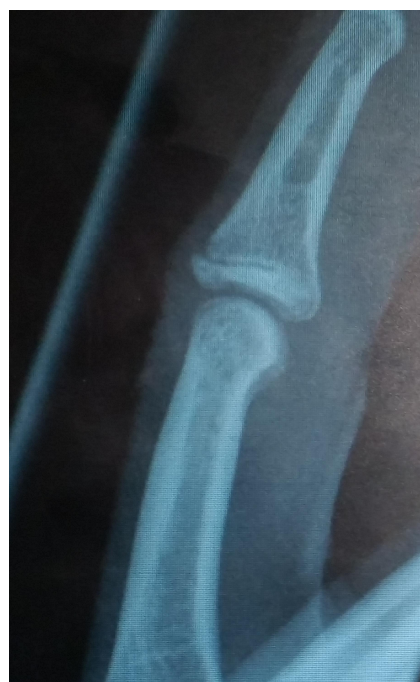

Fig. 3

Figure 2 Middle Finger Proximal Interphalangeal Joint with epiphyseal stress fracture that was not seen on this x-ray that would have shown on MRI.

Figure 3 Same young climber's middle Proximal Interphalangeal Joint now showing the stress fracture having been re-x-rayed a few weeks down the line. (both x-rays used with the permission of the patient and parent).

Types of stress fracture and suggested treatment

The most common fractures are Salter-Harris III.

1. Un-dislocated fracture - the joint is allowed free movement – No stress sports (climbing etc and no volleyball etc) for 8 weeks – then control MRI.
2. Minor displacement splint – or else as above
3. Major surgery

Good results can be achieved if these are treated early and rest adhered to. If treated late and the climber continues to train despite the stress fracture, rotational mal-alignment and partial necrosis of the epiphysis can result.

Further reading

1. Morrison AB, Schöffl VR (2007). Physiological responses to rock climbing in young climbers. Br J Sports Med, 41(12), 852-861.
2. Hochholzer T, Schöffl V (2003). One Move too many... how to understand the injuries and overuse syndromes of rock climbing. Lochner-Verlag, Germany.
3. Hochholzer T, Schöffl VR (2005). Epiphyseal fractures of the finger middle joints in young sport climbers. Wilderness and Environmental Medicine. 16:139-42.
4. Schöffl VR, Schöffl I (2007). Finger pain in rock climbers: reaching the right differential diagnosis and therapy. J Sports Med Phys Fitness, 47:70-80.
5. BMC website: [Should U18s use campus boards?](#)

Acknowledgements

Dr Katharine Rivett, MB ChB, MRCP

Mr Tim Halsey MB ChB, FRCS (Tr&Orth), Dip Hand Surg

Dr Isabelle Schöffl

Prof Dr Volker R. Schöffl, MD, PhD, MHBA